



## **SCAR ENDOMETRIOSIS: PATHOLOGY THE HALLMARK DIAGNOSIS**

**Dr. Sarita Shrivastava<sup>1</sup>**

*<sup>1</sup>Reader, Department of Pathology, Bharti Vidyapeeth Dental College and Hospital, Sector 7, CBD Belapur, Navi Mumbai- 400614, Maharashtra*

**Dr. Minakshi Bhattacharjee<sup>2</sup>**

*<sup>2</sup>Reader, Department of Microbiology, Bharti Vidyapeeth Dental College and Hospital, Sector 7, CBD Belapur, Navi Mumbai- 400614, Maharashtra*

**Dr. Ashwini Panchmahalkar<sup>3</sup>**

*<sup>3</sup>Assistant Professor, Department of Microbiology, Bharti Vidyapeeth Dental College and Hospital, Sector 7, CBD Belapur, Navi Mumbai- 400614, Maharashtra*

### **ABSTRACT**

*Presence of functioning endometria outside the uterine cavity is termed endometriosis. Scar endometriosis is a rare condition wherein endometriosis occurs at the incision site post operatively. Often it is confused with other comparatively common mass or tumors seen and is misdiagnosed. One such rare case of scar endometriosis at the site of cesarean section is reported here. The clinical presentation, diagnosis and treatment approach taken are discussed. Along with this, the case report emphasizes on significance of pathological findings in preliminary as well as confirmative diagnosis of scar endometriosis.*

**KEYWORDS:** *Endometriosis, cesarean section, scar endometriosis, histopathology, pathological findings*

### **INTRODUCTION**

Endometriosis is defined as presence of endometrial glands outside the uterus. Scar endometriosis is rare and usually seen following surgical interventions like cesarean sections or hysterectomy. Its occurrence is explained using different relatable events and implantation of endometrial tissue directly into scar at the time of gynecological procedures is one among them. Often, they are detected when the patient presents with swelling, pain or discharge from the site of surgical incision. Though endometriosis occurs in 5% to 10% of all women in reproductive age group, scar endometriosis is a rarer entity affecting less than 1% of

the cases.<sup>1</sup> Usually, scar endometriosis may occur during an abdominal or pelvic surgery. <sup>2,3</sup> Owing to the non-specific clinical presentation, many a times they are misdiagnosed as abscess, lipoma, hernia, cyst, foreign body, fibroma, tumor or granuloma.<sup>4</sup> Usually patients with scar endometriosis come to gynecology, surgery or dermatology departments and differential diagnosis plays a vital role in identifying it. Clinical history, physical examination and radiological investigations are taken into account for differential diagnosis, and surgical excision stands as a better treatment plan, as medicines can give symptomatic relief, but not reduce the swelling size. However, histopathology which has a crucial part in effectively



omitting the conditions mimicking endometriosis are not always referred. The current case report sought to highlight the role of histopathological examination in efficient diagnosis of scar endometriosis.

### CASE REPORT

The pathology laboratory received an excised mass sample along with skin tags from gynecology department. The mass measured 3 cm×2 cm×1 cm and the attached skin showed a sinus tract formation, pigmentation as well as reddish discoloration. On gross sectioning of the mass, cut sections revealed a few hemorrhagic areas. All the sections were sent for processing and hematoxylin-eosin staining. The slides prepared were subjected to histopathological examination. Sections studied showed stratified squamous lining with endometrial stroma and glands. Along with this, few areas of hemorrhage and hemosiderin laden macrophages were also observed. As all three histological criteria namely; endometrial glands, hemosiderin-laden macrophages and endometrial stroma were seen on microscopy (Figure

1), hence a confirmed diagnosis of scar endometriosis was given.

The clinical history revealed that it was a 45-year-old female who presented with pain and swelling at the site of Cesarean section scar, performed 6 years back. Chief complaints that the patient reported to the gynecologist were increased intensity of pain near the scar site during the menstrual cycle, recurrent episodes of pain associated with periods. This was what brought her attention to the swelling at scar site and prompted her to undergo a checkup. Physical examination detected a swelling measuring 3.5 cm×2.5 cm×1 cm just near the LSCS scar. Since there was history of increased pain and as the patient was ready and convinced for surgery, the mass was excised and sent for histopathological confirmation, with a provisional diagnosis of scar endometriosis. Sonographic findings showed a 3 cm×2 cm×1 cm, oval shaped heterogeneous mass within the right rectus abdominis muscle. All the routine blood tests including FSH, LH and TSH were within normal limits.

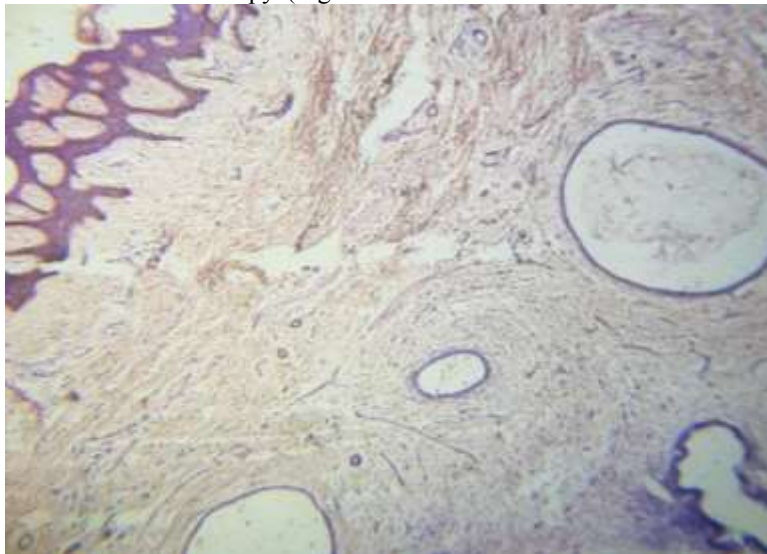


Figure 1: Scar Endometriosis showing endometrial glands, stromal cells and hemosiderin laden macrophages.

### DISCUSSION

The term endometriosis was coined by Karl Von Rokitansky in 1860.<sup>5</sup> Scar endometriosis is a rare condition and may often be confused with other abdominal wall lesions like an abscess, sebaceous cyst, suture granuloma, incisional hernia or lipoma.<sup>6</sup> Different theories have been postulated to understand how endometriosis is caused. Among these, Sampson (in 1868) was the first to suggest that there may be reflux of the endometrial tissue through the fallopian tubes and these may eventually be implanted on the

parietal or pelvic organs. In a similar manner, endometrial tissue might get implanted in the incision site during surgery, and cell proliferation may occur in response to hormones associated with menstrual cycle.<sup>7</sup> All cases of endometrial tissue does not fit this theory of direct implantation and here, comes the other prominent theories into picture. Another theory suggests transport of endometrial cells to adjacent locations during surgical procedures or through lymphatic or hematogenous route, thereby named metastatic theory.<sup>8</sup> Metaplastic theory on the other hand



states, that pluripotential mesenchymal cells may undergo a metaplastic change into endometrial tissue.<sup>8</sup>

Amidst all cases of endometriosis, scar endometriosis is lesser seen and has an incidence of 0.03% to 0.15%.<sup>9,10</sup> Although reports of scar endometriosis following hysterectomy, episiotomy appendectomy and amniocentesis also exists, scar endometriosis associated with LSCS is comparatively seen more.<sup>11</sup> However, variation in the clinical presentation and absence of visible symptoms many a times make it difficult for diagnosis. The classical signs and symptoms like cyclic change in intensity of pain and swelling during menstruation are witnessed in 20% of the cases.<sup>12</sup> Often it is confused with abscess, tumor, hernia, lipoma, granuloma, hematoma or sebaceous cyst when present in the abdominal wall.<sup>4</sup> A person may present with scar endometriosis, as early as months or as late as years after the surgery.<sup>13</sup>

Surgical excision of the mass is the ideal treatment approach adopted, along with hormone replacement therapy for temporary relief of symptoms. Diagnostic aids like Doppler Sonography, CT scans and MRI are widely used methods to differentially diagnose scar endometriosis. However, the most reliable method to diagnose remains histopathology. When two of the classical findings, namely endometrial glands, stromal cells and hemosiderin laden macrophages are observed on microscopy, a confirmative diagnosis of scar endometriosis can be given.<sup>14</sup> In the present report all the three of hallmark characteristics were seen. As pathological confirmation can aptly confirm the clinical suspicion of scar endometriosis, histopathology is a crucial tool.

## CONCLUSION

Scar endometriosis, although rare, is seen at the site of incision in females post gynecological and obstetric surgeries. A suspicious eye towards any mass at the scar site is needed to ensure prompt diagnosis. Confirmative diagnosis is dictated by histopathological analysis. However, a method to arrive at a diagnosis before excision of the mass is a need of the hour. Fine needle aspiration (FNAC) here comes into picture and reports suggest it to be an apt rapid and cost-effective method to arrive at a preliminary diagnosis. In the present case, the excised mass was received at the lab for histopathology and hence, an FNAC could not be done.<sup>15</sup> All in all, understanding the critical role played by pathological findings in diagnosing scar endometriosis and relying on it for preliminary as well as confirmative diagnosis would enable early diagnosis and prompt treatment.

## REFERENCES

1. Francica G, Giardiello C, Angelone G, Cristiano S, Finelli R, Tramontano G. Abdominal wall endometriosis near cesarean delivery scars. *J Ultrasound Med.* 2003;22:1041–7. [[PubMed](#)] [[Google Scholar](#)]
2. Kaloo P, Reid G, Wong F. Cesarean section scar endometriosis: Two cases of recurrent disease and a literature review. *Aust NZ J Obstet Gynaecol.* 2002;42:218–20. [[PubMed](#)] [[Google Scholar](#)]
3. Tanos B, Anteby SO. Cesarean scar endometriosis. *Int J Gynaecol Obstet.* 1994;47:163–6. [[PubMed](#)] [[Google Scholar](#)]
4. Goulart P, Vieira S, Cardoso G, Martino PD, Maires J. Endometriosis implants after cesarean section: more than a scar – a case report. *Acta Obstet Gynecol Port* 2016;10(1):70-73.
5. American college of obstetrician and gynecologist. *Practice bulletin no. 114: management of endometriosis. Obstetrics and Gynecology.* 2010; 164(1):223–36
6. Koger KE, Shatney CH, Hodge K, McClenatha JH. *Surgical scar endometrioma. Surg Gynecol Obstet.* 1993; 177:243–6.  
2. [PMid:8356497](#)
7. Vigno P, et al. Endometriosis epidemiology and etiological factors. *Best practice research clinic Obstet. & gynecol.,* 2004; 18: 17-200
8. Catalina-Fernández I, López-Presa D, Sáenz-Santamaria J. Fine needle aspiration cytology in cutaneous and subcutaneous endometriosis. *Acta Cytol* 2007; 51:380-4
9. Francica G, Giardiello C, Angelone G, Cristiano S, Finelli R, Tramontano G. Abdominal wall endometriosis near cesarean delivery scars. *J Ultrasound Med.* 2003; 22:1041–7. <https://doi.org/10.7863/jum.2003.22.10.1041>  
[PMid:14606559](#)
10. Kaloo P, Reid G, Wong F. Cesarean section scar endometriosis: Two cases of recurrent disease and literature review. *Aust NZ J Obstet Gynaecol.* 2002; 42:218–20. [https://doi.org/10.1111/j.0004-8666.2002.210\\_5.x](https://doi.org/10.1111/j.0004-8666.2002.210_5.x)
11. Goel P, Sood SS, Dalal A, Romilla. Cesarean scar endometriosis-report of two cases. *Indian J Med Sci* 2005;59:495-8.
12. Ding CD, Hsu S. Scar endometriosis at the site of cesarean section. *Taiwanese J Obstet Gynecol.* 2006; 3:247–9. [https://doi.org/10.1016/S1028-4559\(09\)60234-5](https://doi.org/10.1016/S1028-4559(09)60234-5)
13. Chatterjee SK. Scar endometriosis: A clinicopathologic study of 17 cases. *Obstet Gynecol.* 1980; 56:81–4. [PMid:7383492](#)
14. Pathan SK, Kapila K, Haji BE, Mallik MK, Al-Ansary TA, George SS, et al. *Cytomorphological*



*spectrum in scar endometriosis: A study of eight cases. Cytopathology 2005;16:94-9.*

15. Pachori G, Sharma R, Sunaria RK, Bayla T. Scar endometriosis: Diagnosis by fine needle aspiration. *J Cytol.* 2015;32(1):65-67. doi:10.4103/0970-9371.155243