



Chief Editor

Dr. A. Singaraj, M.A., M.Phil., Ph.D.

Editor

Mrs.M.Josephin Immaculate Ruba

Editorial Advisors

1. **Dr.Yi-Lin Yu**, Ph. D
Associate Professor,
Department of Advertising & Public Relations,
Fu Jen Catholic University,
Taipei, Taiwan.
2. **Dr.G. Badri Narayanan**, PhD,
Research Economist,
Center for Global Trade Analysis,
Purdue University,
West Lafayette,
Indiana, USA.
3. **Dr. Gajendra Naidu.J.**, M.Com, LL.M., M.B.A., PhD. MHRM
Professor & Head,
Faculty of Finance, Botho University,
Gaborone Campus, Botho Education Park,
Kgale, Gaborone, Botswana.
4. **Dr. Ahmed Sebihi**
Associate Professor
Islamic Culture and Social Sciences (ICSS),
Department of General Education (DGE),
Gulf Medical University (GMU), UAE.
5. **Dr. Pradeep Kumar Choudhury**,
Assistant Professor,
Institute for Studies in Industrial Development,
An ICSSR Research Institute,
New Delhi- 110070.India.
6. **Dr. Sumita Bharat Goyal**
Assistant Professor,
Department of Commerce,
Central University of Rajasthan,
Bandar Sindri, Dist-Ajmer,
Rajasthan, India
7. **Dr. C. Muniyandi**, M.Sc., M. Phil., Ph. D,
Assistant Professor,
Department of Econometrics,
School of Economics,
Madurai Kamaraj University,
Madurai-625021, Tamil Nadu, India.
8. **Dr. B. Ravi Kumar**,
Assistant Professor
Department of GBEH,
Sree Vidyanikethan Engineering College,
A.Rangampet, Tirupati,
Andhra Pradesh, India
9. **Dr. Gyanendra Awasthi**, M.Sc., Ph.D., NET
Associate Professor & HOD
Department of Biochemistry,
Dolphin (PG) Institute of Biomedical & Natural Sciences,
Dehradun, Uttarakhand, India.
10. **Dr. D.K. Awasthi**, M.SC., Ph.D.
Associate Professor
Department of Chemistry, Sri J.N.P.G. College,
Charbagh, Lucknow,
Uttar Pradesh. India

ISSN (Online) : 2455 - 3662
SJIF Impact Factor :5.148

EPRA International Journal of Multidisciplinary Research

Monthly Peer Reviewed & Indexed
International Online Journal

Volume: 4 Issue:12 December 2018



Published By :
EPRA Journals

CC License



**EPRA International Journal of
Multidisciplinary Research (IJMR)**

ANTICARDIOLIPIN ANTIBODIES AND ISCHEMIC STROKE IN CHILDREN – CASE REPORT

¹Jose Maria Pereira de Godoy, MD, PhD

¹Cardiology and Cardiovascular Surgery
Department of the Medicine School in São
José do Rio Preto (FAMERP),
CNPq (National Council for Research and
Development)-Brazil

²Ana Carolina Pereira de Godoy, MD

²Resident of the Pediatrics Unit Intensive
Therapy of Santa Casa de São Paulo,
Brazil and Research Group of Clínica
Godoy, São Jose do Rio Preto, Brazil

ABSTRACT

The cases of a two-year-old boy and a three-year-old boy, who presented with cerebral strokes, are reported. They were submitted to computerized tomography, angioresonance, and echocardiogram and anticardiolipin antibody measurement. Cerebral stroke was confirmed in both cases and the anticardiolipin antibodies were found to be elevated in one case and borderline in the other. Clinical treatment was successful and the children evolved well.

KEY WORDS: *Stroke, Children, Anticardiolipin, Antibodies.*

INTRODUCTION

Childhood ischemic stroke, including arterial ischemic stroke and sinovenous thrombosis, is relatively rare in children but can result in devastating morbidity and mortality ⁽¹⁾. Stroke in children is infrequent, with an incidence of 2.6 and 3.1/100,000 in Caucasian and Negroid children, respectively. ⁽²⁾

With increasing vigilance among physicians and improved neuroimaging modalities, the diagnosis of childhood stroke is now made earlier, with increasing frequency and greater accuracy ³. Lack of knowledge of the underlying pathogenic mechanisms results in diagnostic challenges and complicates therapeutic decisions, as reflected in divergent recommendations in three sets of pediatric stroke

guidelines in particular relating to antiplatelet therapy, anticoagulation and thrombolysis ⁴.

Studies demonstrate that antiphospholipid antibodies are a risk factor in ischaemic stroke in children^(5,6). Antiphospholipid antibodies consist of a heterogeneous group of circulating autoantibodies against anionic phospholipids⁽⁷⁾. The objective of this study is to emphasize the association of the antibodies anticardiolipin with the stroke in children.

Case 1

A three-year-old apparently healthy Caucasian child was hospitalized with hemiplegia of the left side. The mother reported that her child at first appeared to be well but after she noticed a change in his behavior. On the following day, the patient lost muscle strength and medical assistance was sought. A cerebral

computerized tomography was performed which gave a normal result. Five days later he presented with an abrupt beginning of aphasia. In the neurological examination, the patient was conscious and presented a passive attitude, aphasia of expression and both muscular hypotonia and hemiplegia on the left side. Other tests were made including echocardiogram, Doppler echocardiogram of both the carotid arteries which were normal. A cerebral angioresonance showed areas of local hypersignals in the left parietal white matter, without any effect on the mass-dimension proportion. The lateral ventricles presented with normal dimensions and morphology. A cerebral scintigram showed signs of Barrier hematoencephalic lesions with a traced passage in the topography of the right hemisphere. Additionally an electroencephalogram demonstrated a diffused slowing of the cerebral electrical activity and depression of the cerebral electrical activity in the right frontal region. Evaluation of the anticardiolipin antibodies levels was achieved by Enzyme-Linked Immunoabsorbent Assay (ELISA) for quantitative measurement of IgG and IgM antibodies against cardiolipins in serum. Values > 10 GPL units/ml and 7 MPL units/ml for IgG and IgM respectively were considered elevated as recommended by the kit manufacturer. Values of 7 - 10 GPL units/ml and 4 - 7 MPL units/ml for IgG and IgM respectively were considered borderline cases. The results were borderline for both IgG anticardiolipin (7.28 GPL units/mL) and IgM (6.92 MPL units/mL).

Case 2

A two-year-old Caucasian male child was hospitalized after a sudden episode of muscular weakness on the right side. In a neurological examination, the patient was able to speak normally, he presented with muscular hypotonia with complete hemiparesis and the tendon reflexes suppressed all on the right side; the cranium halves were without alterations. Initial cerebral tomography and echocardiogram were normal. Angioresonance evidenced areas of local hypersignal in the frontal lobes and parietal to the right, in the base nucleus to the right and the left parietal white matter, without any effect on the mass-dimension proportion. The lateral ventricles presented with normal dimensions and morphology.

Assay (ELISA) for quantitative measurement of IgG and IgM antibodies against cardiolipins in serum. Values > 10 GPL units/ml and 7 MPL units/ml for IgG and IgM respectively were considered elevated as recommended by the kit manufacturer. Values of 7 - 10 GPL units/ml and 4 - 7 MPL units/ml for IgG and IgM respectively were considered borderline cases. The evaluation of anticardiolipin antibodies levels evidenced elevated levels for IgG anticardiolipin (20 GPL units/mL) and normal levels for IgM (3.7 MPL

units/mL) and after four week a new evaluation with positive results.

DISCUSSION

Strokes in children are rare occurrences where the risk factors are not always detected. Congenital and hereditary thrombophilias are associated with several thrombotic clinical conditions among which are strokes in children ⁽¹⁻⁹⁾, and thus they should be considered. In this study, the association between positive levels for anticardiolipin antibodies and strokes in children was demonstrated. The child in case 1 presented two thrombotic events in one week. Measurements of these antibodies proved to be borderline on two occasions. No previous publications have reported borderline levels of these antibodies in infant stroke cases. In one study assessing peripheral arterial thrombosis, an association between borderline levels and peripheral arterial thrombotic episodes was detected. ⁽⁵⁾ This data suggests a greater importance should be placed on this association.

The treatment chosen in the cases reported in this paper was initially anticoagulation using heparin followed by a long-term use of aspirin. Long-term aspirin use was reported in one other study. ⁽¹⁰⁾ However, for adults, chronic anticoagulation is recommended. ⁽¹¹⁾ The small number of studies involving infant patients suggests the option of aspirin and a careful long-term evaluation of these patients to identify the possibility of the presence of re-thrombosis at later occasions.

REFERENCES

1. Cervera R, Serrano R, Pons-Estel GJ, et al on behalf of the Euro-Phospholipid Project Group (European Forum on Antiphospholipid Antibodies). Morbidity and mortality in the antiphospholipid syndrome during a 10-year period: a multicentre prospective study of 1000 patients. *Annals of the Rheumatic Diseases* 2015;74:1011-1018.
2. Merlin E, Doré E, Chabrier S, Biard M, Marques-Verdier A, Stéphan JL. A case of infantile de novo primary antiphospholipid syndrome revealed by a neonatal arterial ischemic stroke. *J Child Neurol*. 2012 Oct;27(10):1340-2. Merlin E¹, Doré E, Chabrier S, Biard M, Marques-Verdier A, Stéphan JL.
3. Riel-Romero RM, Kalra AA, Gonzalez-Toledo E. Childhood and teenage stroke. *Neurol Res*. 2009 Oct;31(8):775-84.
4. Eleftheriou D, Ganesan V. Controversies in childhood arterial ischemic stroke and cerebral venous sinus thrombosis. *Expert Rev Cardiovasc Ther*. 2009 Jul;7(7):853-61.
5. Pilarska E. The significance of antiphospholipid antibodies in ischemic stroke in children in light of the most current studies. *Przegl Lek*. 2001;58(1):22-4.
6. De Godoy JM, de Godoy MF, Braile DM. Recurrent thrombosis in patients with deep vein thrombosis and/or

- venous thromboembolism associated with anticardiolipin antibodies. *Angiology*. 2006 Jan-Feb;57(1):79-83.
7. Godoy JMP, Braile DM, Torres CAA, Godoy MF. Prevalence of Anticardiolipin Antibodies in Peripheral Arterial Thrombosis. *Angiology* 2000; 51:473-77.
8. Berkun Y, Simchen MJ, Strauss T, Menashcu S, Padeh S, Kenet G. Antiphospholipid antibodies in neonates with stroke--a unique entity or variant of antiphospholipid syndrome? *Lupus*. 2014 Sep;23(10):98693. doi:10.1177/0961203314531842. Epub 2014 Apr 11.

APPENDIX

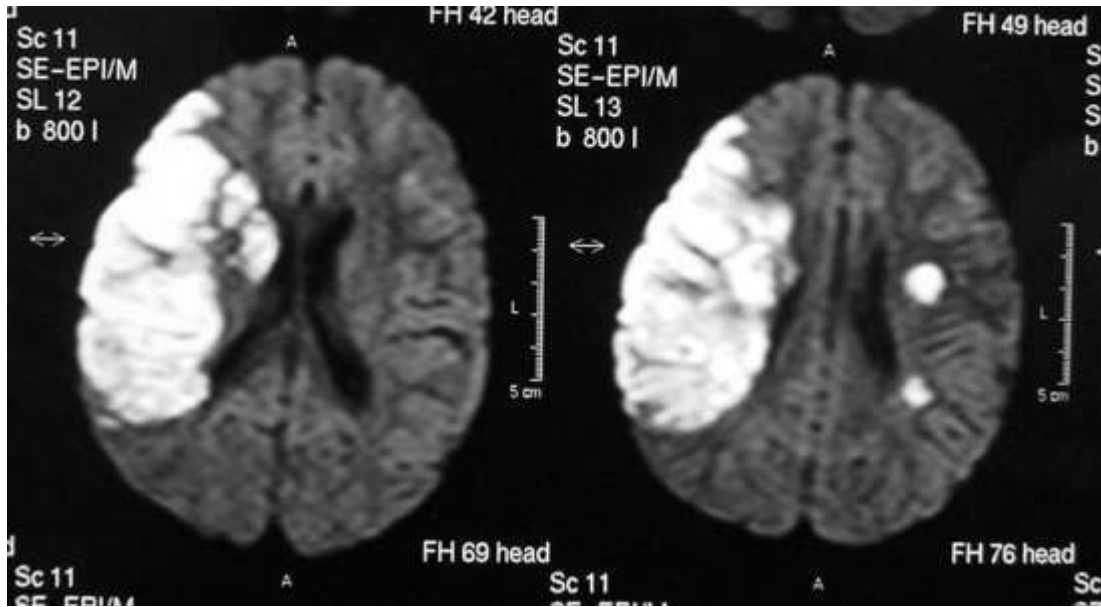


Figure 1. Evidenced areas of local hypersignal in the frontal lobes and parietal to the right, in the base nucleus to the right and the left parietal white matter, without any effect on the mass-dimensions proportion. The lateral ventricles presented with normal dimensions and morphology.